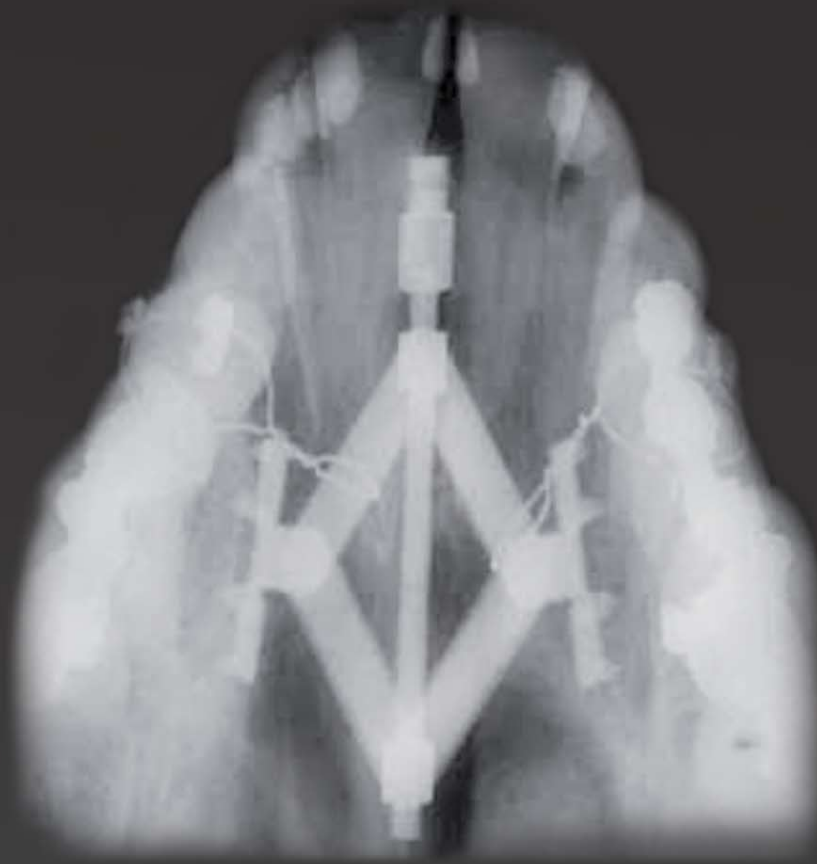

Distraction Osteogenesis



## Rotterdam Palatal Distractor

*for surgically assisted rapid maxillary expansion*



### **Introduction**

*Transverse maxillary deficiency in adolescents and adults is frequently seen in syndromic as well as non-syndromic patients including cleft patients. The transverse hypoplasia can be corrected by means of a surgically assisted rapid maxillary expansion.*

*The treatment is an association of orthodontics and surgical procedures and provides dental arch space for lining up the teeth. The procedure also causes a substantial enlargement of the maxillary apical base and of the palatal vault, providing space for the tongue for correct swallowing and thus preventing relapse. In addition, a distinct subjective improvement in nasal breathing associated with enlargement of the nasal valve towards normal values is seen with an increase of nasal volume in all compartments.*

*Traditionally, the distractors for expansion are tooth-borne devices, i.e. hyrax appliances, which might have some serious disadvantages:*

- 1. periodontal problems like buccal root resorption and cortical fenestration*
- 2. segmental tipping and anchorage-tooth tipping*
- 3. dental caries in syndromic patients with poor oral hygiene*

*In contrast, with bone-borne distractors applied at a higher level in the palatal vault, most of the maxillary expansion is orthopaedic and at a more mechanically desired level.*

*In addition, the forces are directly applied to the bone and no tooth tipping and other unwelcome side effects are to be expected.*

## Rotterdam Palatal Distractor



*Developed in cooperation with*

K.G.H. van der Wal, D.D.S., M.D. Ph.D.  
E.B. Wolvius, D.D.S., M.D. Ph.D.  
Dept. of Oral & Maxillofacial Surgery  
and Craniofacial Centre,  
Erasmus University Medical Centre Rotterdam,  
The Netherlands

### *Indications*

- Extreme transverse maxillary deficiency in syndromatic and non-syndromatic patients
- Anterior crowding and buccal corridors

### *Relative contraindications*

- Class II deep bite; the distractor or the small activation rod on the palate may interfere with the teeth of the mandible. This can be overcome by placing the Rotterdam Palatal Distractor more distally or by wearing an occlusal splint during the distraction and consolidation period.

### *Absolute contraindications*

- Extreme low palate; in case of an extreme low palate, the pins of the abutment plates will lose fixation and the distractor will not be stable.
- A general contraindication is an immune deficiency and irradiation.

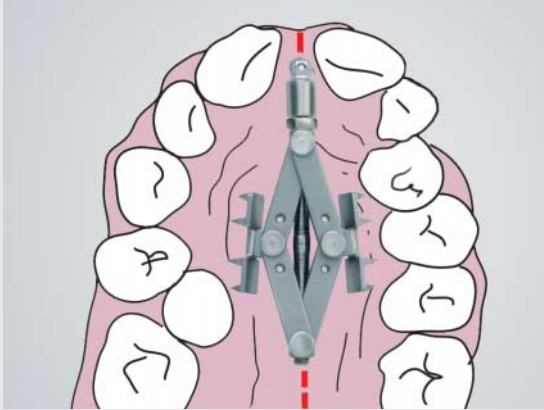
### *Benefits*

- Easily placed and activated
- No dental anchorage
- No screw fixation with possible damage to the (pre-)molar roots
- Easily blocked with a stainless steel wire
- Allows simultaneous orthodontic treatment with fixed appliances
- Easily removed with local anaesthesia

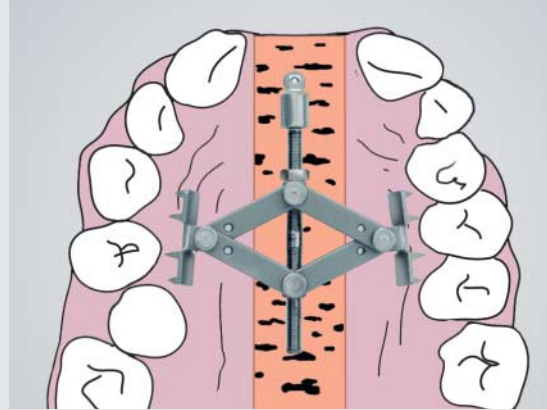
### *Special Notes*

- For primary stabilization, the Rotterdam Palatal Distractor has to be slightly activated.
- One should realize that due to the mechanical principle of a car jack equal activation during the distraction period will result in a progressively decreasing distraction length. Therefore, in the course of the distraction, the rhythm of activation changes (see page 5).
- Patients with the Rotterdam Palatal Distractor have to keep up oral hygiene; regular visit to the oral hygienist is recommended.

## Intraoperative procedure



**Fig. 1:** Rotterdam Palatal Distractor, start position



**Fig. 2:** During distraction period

### *Intraoperative approach*

Standard corticotomies of the anterior, lateral and median bony supports of the maxilla are performed. The palatal gingiva of the premolars is infiltrated with local anaesthesia including a vasoconstrictor.

Firstly, the Rotterdam Palatal Distractor is positioned temporarily with the abutment plates on the mucosa over the roots of the first or second premolars. The activation rod is in the midline and must not interfere with the lower teeth in occlusion. The distractor is slightly activated. Thus the print of the plates is clearly visible on the mucosa. Now the palatal mucosa on the anterior and occlusal side directly around the abutment plates is incised. The distractor is deactivated and removed.

The palatal mucosa slightly smaller than the abutment plate is removed. Local haemostasis is performed. The Rotterdam Palatal Distractor is placed again with the plates now on the bone. The distractor is slightly activated so the pins penetrate the bone stabilizing the distractor and, as a consequence, the vector.

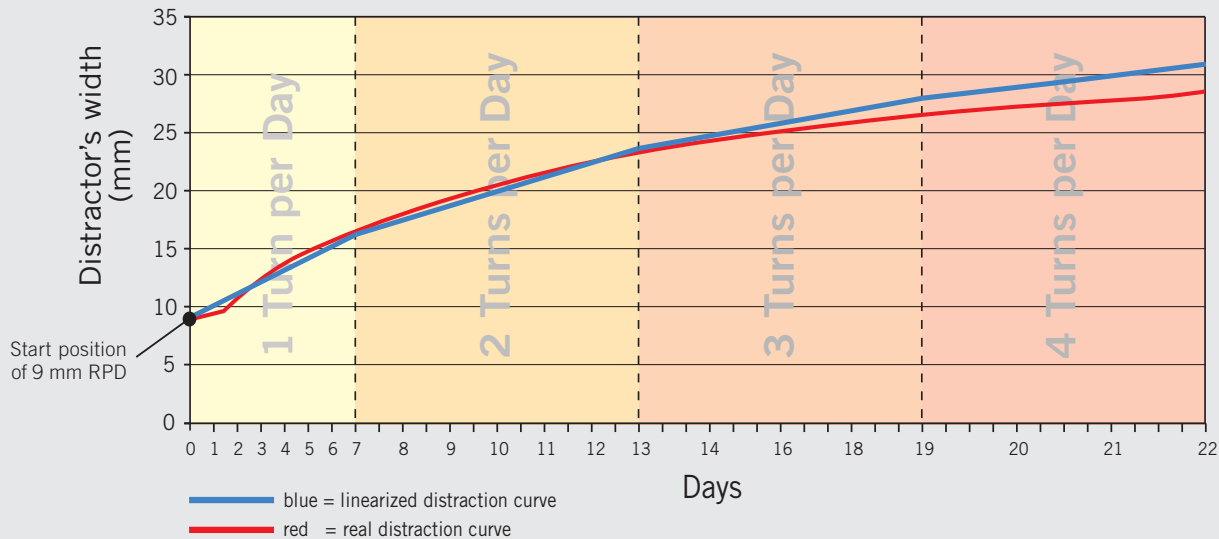
### *Note:*

Do not intend to place the distractor epimucosally (on the mucosa), as its sharp spikes might irritate the palatal mucosa and may cause pain and discomfort for the patient.

The number of turns is counted in order to know where to start in the distraction protocol. Finally, the distractor is secured with stainless steel wires around the premolars on both sides.

## Distraction Diagram

showing the width of a 9 mm Rotterdam Palatal Distractor in relation to active distraction time



### Distraction Protocol

Due to the mechanical principle (trigonometric function) of a car jack, equal activation will result in a progressively decreasing distraction length (see figure). Activation with 0.6 turn ( $0.6 \times 360^\circ = 216^\circ$ ) at the start of the distraction will result in a distraction length of 1 mm. After 5 mm of distraction, 1.3 turns ( $1.3 \times 360^\circ = 468^\circ$ ) are necessary to achieve the same distraction length of 1 mm. In the graphic, the changing length during the distraction period is demonstrated. As a result a distraction of exactly 1 mm per day is not feasible. To come close to the 1 mm and to achieve optimal patient's comfort, different distraction rhythms have been selected:

#### 1<sup>st</sup> interval:

Closed distractor until 7 complete turns: 1 turn per day

#### 2<sup>nd</sup> interval:

From 7 turns (distractor is opened for approx. 7 mm) until 13 complete turns: 2 turns per day

#### 3<sup>rd</sup> interval:

From 13 turns (distractor is opened for approx. 14 mm) until 19 complete turns: 3 turns per day

#### 4<sup>th</sup> interval:

From 19 turns (distractor is opened for approx. 17 mm) until maximal distraction length: 4 turns per day

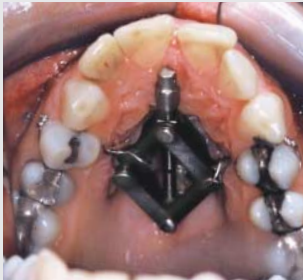It is very important to note the opening length (amount of turns) of the distractor during the placement in order to know where to start in the scheme respectively in which interval.

- Latency period: 7 days
- Distraction is performed according to the different intervals by using the patient screwdriver (item no. 51-555-95-07).
- Consolidation period after distraction: 3 months
- Orthodontic treatment can already be started or continued during the consolidation period

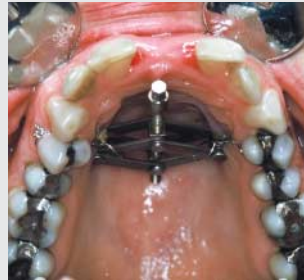## Clinical examples

### Case 1 – Non-syndromatic patient

Non-syndromatic patient with mandibular retrognathia and transverse maxillary hypoplasia



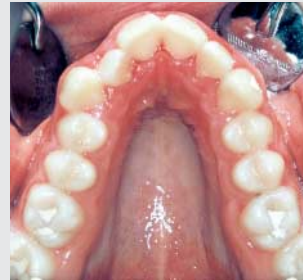**Fig. 1:** Submucosal application of the distractor.



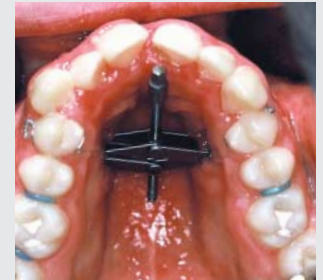**Fig. 2:** At the end of distraction the maxilla has been widened.

### Case 2 – Non-syndromatic patient

Non-syndromatic patient with mandibular prognathia, open bite and narrow-tapered arch form



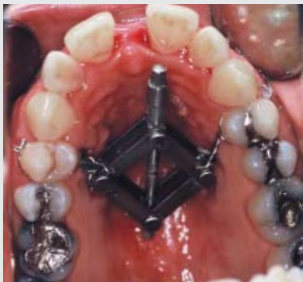
**Fig. 1:** Narrow-tapered arch form with anterior crowding.



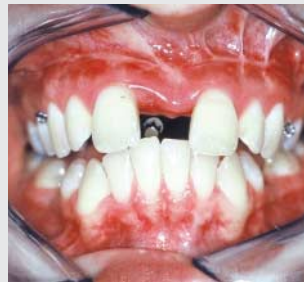**Fig. 2:** The maxilla has been widened and already the central incisors have migrated mesially without orthodontics.

### Case 3 – Non-syndromatic patient

Non-syndromatic patient with mandibular retrognathia and transverse maxillary hypoplasia



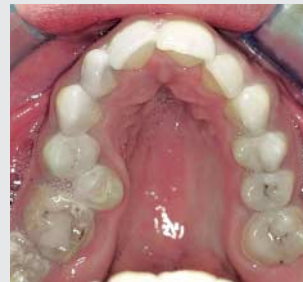**Fig. 1:** The distractor is slightly out of the midline but without any clinical consequences.



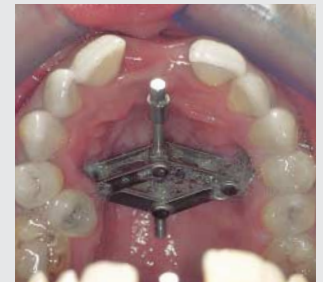**Fig. 2:** The maxilla has been widened; a clear central diastema appears which can be closed orthodontically.

### Case 4 – Syndromatic patient

Syndromatic patient with Treacher Collins including transverse maxillary hypoplasia



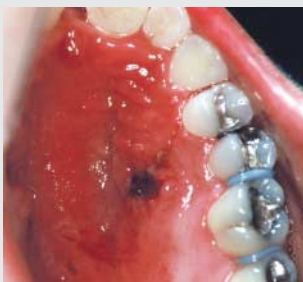**Fig. 1:** Narrow-tapered arch form with high palate and anterior crowding.



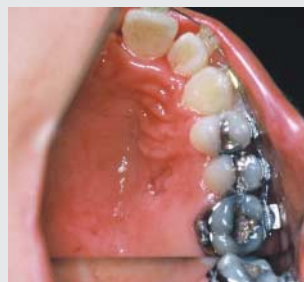**Fig. 2:** Clinical situation directly after end of distraction period.

### Removal of the distractor

At the end of the consolidation period, the distractor can be removed in an out-patient clinic. The palatal mucosa surrounding the distractor is infiltrated with local anaesthesia including a vasoconstrictor. The stainless steel wires are removed, the distractor is deactivated and removed (picture 1). The healing of the mucosa is normally complete within a week (picture 2).



**Fig. 1:** Directly after removal of the distractor.



**Fig. 2:** Complete healing of the mucosa after one week.

## Ordering details and Literature



51-555-09-09

**Rotterdam Palatal Distractor for patients with congenital deformities:**  
For extreme narrow maxillas particular in syndromatic patients. Especially in these cases, there is no space for a conventional hyrax appliance or bone-borne type distractors that have to be fixated with screws.  
**closed: 9 mm** (distance from plate to plate)  
**maximal open: 28 mm**



51-555-13-09

**Rotterdam Palatal Distractor for patients with regular transverse maxillary hypoplasia:**  
**closed: 13 mm** (distance from plate to plate)  
**maximal open: 32 mm**

### Design of the Distractor

The Rotterdam Palatal Distractor is a bone-borne distractor which can easily be placed and activated. It has the design of a car jack and is totally made of titanium grade II. By activating the distractor, the 2 mm long pins of the two abutment plates will penetrate the bone and the device is stabilized automatically. No screws are necessary to fixate the distractor to the bone. At the end of the distraction period, the distractor is easily blocked with a stainless steel wire.



51-555-90-07  
10 cm/3 7/8"  
Patient screwdriver  
hockey stick-like

51-555-91-07  
8 cm/3 1/8"  
Patient screwdriver

51-555-85-07  
14 cm/5 4/8"  
Patient screwdriver  
straight



51-555-95-07  
14.5 cm/5 9/8"  
Patient screwdriver  
angled

### References

- Bell WH, Epker BN. Surgical-orthodontic expansion of the maxilla. *Am J Orthod* 1976; 50: 517-528.
- Bressmann T, Sader R, et al. Nasalance distance and ratio: two new measures. *Cleft Palate-Craniofacial Journal* 2000; 37: 248-256.
- Gerlach KL, Zahl C. Palatal distractor. An innovative approach for palatal expansion. *Mund Kiefer Gesichtschir* 2002; 6: 446-449.
- Gerlach KL, Zahl C. Transversal palatal expansion using a palatal distractor. *J Orofac Orthop* 2003; 64: 443-449.
- Glassman AS, Nahigian SJ, Medway JM, Aronowitz HI. Conservative surgical orthodontic adult rapid palatal expansion: sixteen cases. *Am J Orthod* 1984; 86: 207-213.
- Mommaerts MY. Transpalatal distraction as a method of maxillary expansion. *Br J Oral Maxillofac Surg* 1999; 37: 268-72.
- Neubert J, Somsiri S, Howaldt HP, Bitter K. Surgical expansion of midpalatal suture by means of modified Le Fort I osteotomy. *Dtsch Z Mund Kiefer Gesichtschir* 1989; 13: 57-64.
- Neyt NMF, et al. Problems, obstacles and complications with transpalatal distraction in non-congenital deformities. *J Craniomaxillofac Surg* 2002; 30: 139-143.
- Pinto PX, Mommaerts MY, et al. Immediate postexpansion changes following the use of the transpalatal distractor. *J Oral Maxillofac Surg* 2001; 59: 994-1000.
- Profitt WR. Contemporary orthodontics, third edition, 2000. Penny Rudolph, Mosby, Inc, St Louis, USA.
- Wriedt S, Kunkel M, et al. Surgically assisted rapid palatal expansion, an acoustic rhinometric, morphometric and sonographic investigation. *J Orofac Orthop/Fortschr Kieferorthop* 2001; 62: 107-115.

## KLS Martin Group

**Karl Leibinger Medizintechnik GmbH & Co. KG**  
78570 Mühlheim · Germany  
Tel. +49 7463 838-0  
info@klsmartin.com

**KLS Martin GmbH + Co. KG**  
79224 Umkirch · Germany  
Tel. +49 7665 9802-0  
info@klsmartin.com

**Stuckenbrock Medizintechnik GmbH**  
78532 Tuttlingen · Germany  
Tel. +49 7461 165880  
verwaltung@stuckenbrock.de

**Rudolf Buck GmbH**  
78570 Mühlheim · Germany  
Tel. +49 7463 99516-30  
info@klsmartin.com

**KLS Martin France SARL**  
68200 Mulhouse · France  
Tel. +33 3 8951 3150  
france@klsmartin.com

**Martin Italia S.r.l.**  
20864 Agrate Brianza (MB) · Italy  
Tel. +39 039 605 6731  
italia@klsmartin.com

**Martin Nederland/Marned B.V.**  
1271 AG Huizen · The Netherlands  
Tel. +31 35 523 4538  
nederland@klsmartin.com

**KLS Martin UK Ltd.**  
Reading RG1 3EU · United Kingdom  
Tel. +44 1189 000 570  
uk@klsmartin.com

**Nippon Martin K.K.**  
Osaka 541-0046 · Japan  
Tel. +81 6 62 28 9075  
nippon@klsmartin.com

**KLS Martin L.P.**  
Jacksonville, FL 32246 · USA  
Tel. +1 904 641 7746  
usa@klsmartin.com

**KLS Martin do Brasil Ltda.**  
CEP 04.531-011 São Paulo · Brazil  
Tel.: +55 11 3554 2299  
brazil@klsmartin.com

**KLS Martin Australia Pty Limited**  
Artarmon NSW 2064 · Australia  
Tel.: +61 2 9439 5316  
australia@klsmartin.com

**KLS Martin Malaysia Sdn. Bhd.**  
10200 Penang · Malaysia  
Tel. +604 263 2566  
malaysia@klsmartin.com

**Gebrüder Martin GmbH & Co. KG**  
Representative Office  
121471 Moscow · Russia  
Tel. +7 499 792-76-19  
russia@klsmartin.com

**Gebrüder Martin GmbH & Co. KG**  
Representative Office  
201203 Shanghai · China  
Tel. +86 21 5820 6251  
china@klsmartin.com

**Gebrüder Martin GmbH & Co. KG**  
Representative Office  
Dubai · United Arab Emirates  
Tel. +971 4 454 16 55  
middleeast@klsmartin.com

### **Gebrüder Martin GmbH & Co. KG**

#### **A company of the KLS Martin Group**

KLS Martin Platz 1 · 78532 Tuttlingen · Germany  
Postfach 60 · 78501 Tuttlingen · Germany  
Tel. +49 7461 706-0 · Fax +49 7461 706-193  
info@klsmartin.com · www.klsmartin.com

